

# A comparative study of lateral cephalograms and cone-beam computed tomographic images in upper airway assessment

Mariana B. Vizzotto, Gabriela S. Liedke, Eduardo Luiz Delamare, Heraldo D. Silveira, Vinícius Dutra and Heloísa E. Silveira

Department of Surgery and Orthopedics, School of Dentistry, Federal University of Rio Grande do Sul, Brazil

*Correspondence to:* Mariana Boessio Vizzotto, Department of Surgery and Orthopedics, School of Dentistry, Federal University of Rio Grande do Sul, Ramiro Barcelos Street, 2492/503 Porto Alegre 90035-003, Rio Grande do Sul, Brazil. E-mail: mari\_vizzotto@yahoo.com.br

**SUMMARY** The purpose of this study was to evaluate the accuracy of airway measurements from lateral cephalograms, cone-beam computed tomographic (CBCT) lateral reconstructions, and CBCT axial planes, as well as to correlate these findings with area measurements acquired with the latter imaging method. Landmarks were defined for the measurements of naso- and oropharynx of 30 patients (12 males and 18 females, mean age 17.5 years), for different planes, using linear antero-posterior measurements and the corresponding area. Analysis of variance showed significant differences in the linear measurements of the oropharynx between the two methods, although all measurements assessed corresponded to the respective areas. The linear measurements of the airway space obtained using the different techniques correlated positively with the respective area measurements, which demonstrate the reliability of the investigated techniques.

## Introduction

Upper airway evaluation and assessment of its interactions with craniofacial development and growth has been the subject of interest in several health care-related research areas such as otolaryngology, speech pathology, paediatrics, and dentistry (Watson *et al.*, 1968; Solow *et al.*, 1984; Bittencurt, 2002).

Individual variations in airway morphology are commonly found due to inheritance and functional disorders (Subtelny and Baker, 1956; Fujiki and Rossato, 1999). Regardless of its cause, any airway disorder must be identified, diagnosed, and, if possible, treated. Several methods have been proposed in order to assess the airway, including cephalometry, rhinoendoscopy, and tomography (Filho *et al.*, 2001).

Upper airway alterations are occasionally identified at the beginning of orthodontic treatment, after cephalometric evaluation. However, the two-dimensional representation of three-dimensional structures as afforded by the radiographic image in cephalometry provides limited diagnostic information.

Cone-beam computed tomography (CBCT) was developed with the purpose of providing a superior imaging modality in dentomaxillofacial diagnosis, by offering improved conditions for visualization and image manipulation on a 1:1 scale and with a considerably lower radiation dose, when compared with medical CT (Mozzo *et al.*, 1998; Holberg *et al.*, 2005; Scarfe *et al.*, 2006). In addition to reconstructed lateral images, this method offers the possibility of panoramic,

orthogonal projections and multiplanar reconstructions (Araki *et al.*, 2004; Farman and Scarfe, 2006; Nuernberg and Vilella, 2006; Moshiri *et al.*, 2007).

A number of reference measurements are attributed to the airway and several studies have attempted to establish normal values for some of these (McNamara, 1981; Nuernberg and Vilella, 2006; Moshiri *et al.*, 2007). Nevertheless, the presented methods vary widely. Most of these studies divide the upper airway into oro- and nasopharyngeal regions. The cephalometric analysis of McNamara (1981) indicates the nasopharynx as a linear measurement of a midpoint on the posterior wall of the soft palate up to the posterior wall of the pharynx, at the point where the most evident airway constriction is detected. The oropharynx is assessed radiographically by the pharyngeal width at the point where the posterior border of the tongue crosses the lower border of the mandible up to the posterior wall of the pharynx.

The purpose of this study was to evaluate the accuracy of airway measurements from lateral cephalograms, CBCT lateral reconstructions, and CBCT axial planes, as well as to correlate these findings with area measurements acquired with the latter imaging method.

## Materials and methods

The orthodontic files of 30 patients (12 males and 18 females, mean age 17.5 years) obtained from the Oral Radiology Department of the Federal University of Rio

Grande do Sul, that included both a conventional cephalogram and a CBCT scan acquired using the same protocol, were analysed. All patients signed an informed consent and the research project had previously been approved by the Institutional Review Board, Federal University of Rio Grande do Sul.

CBCT scans were obtained using an i-CAT classic tomography scanner (Imaging Sciences International, Hatfield, Pennsylvania, USA). The scanning parameters were 3–8 mA, 120 kVp, 0.5 mm focal spot, field of view 13 cm, and a voxel size of 0.25 mm. All patients remained in centric occlusion and had their heads orientated so that their midsagittal plane was positioned perpendicular, with the Frankfort plane parallel to the floor. The images were imported into i-CAT Vision software for standardization with the purpose of establishing orthogonal relationships between the following planes: palatal plane (anterior nasal spine to posterior nasal spine); a plane formed by the infraorbital foramina and a plane formed by the superior aspect of the external acoustic meatus bilaterally, to make lateral reconstructed cephalograms. Axial images were obtained exactly at the measurement height observed on reconstructions of the sagittal plane.

The lateral cephalograms were acquired with an X Mind Tome Ceph (Cranex Tome—Soredex, Milwaukee, Wisconsin, USA, 85 kVp, 10 mA). A cephalostat ensured head positioning, and the central beam was aimed at the left side of the face with a 10 per cent standardized magnification. All radiographs were processed in an automatic programme and digitized using a transparency scanner (Scanjet 3800, Hewlett-Packard, Palo Alto, California, USA) and saved as JPeg files. The digitization parameters adopted in this study were 300 dpi resolution, 8 bits, original size, and manual adjustments of brightness and contrast. The digital images were positioned with the palatal plane parallel to the floor.

The following pre-established airway measurements were marked on the sagittal plane (Figure 1):

**Nasopharynx:** The most posterior point at the height of the posterior nasal spine, from which a line was traced parallel to the floor extending to the posterior wall of the pharynx.

**Oropharynx:** A point at which the tongue image crossed the lower border of the mandible, from which a line parallel to the floor extended to the posterior wall of the pharynx.

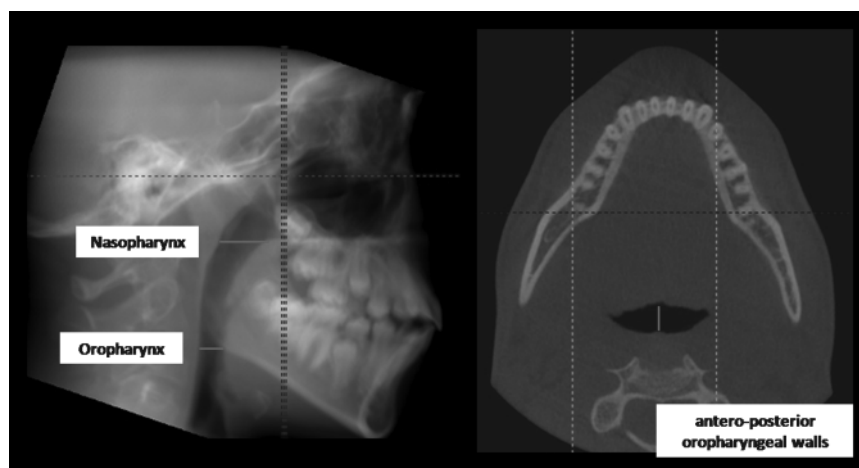
Image Tool software version 3.0 (UTHSCSA, University of Texas Health Science Centre, San Antonio, Texas, USA) was used for image analysis. All images were calibrated prior to measurement: a metallic marker was used as the reference for the radiographic images and window size for the CBCT images. Measurements were performed by direct mouse cursor detection and the identified values were tabulated and filed using MS Excel 2003 (Microsoft, Redmond, Washington, USA). The measurements were carried out blind, by a calibrated examiner (GSL) on two occasions with an interval of 15 days (intraclass correlation coefficient 8.1–9.5).

Data underwent coding in order to ensure blind interpretation and analysis was performed using the Statistical Package for Social Sciences, version 15.0 (SPSS Inc., Chicago, Illinois, USA).

## Results

Table 1 shows the means of the airway measurements tested by analysis of variance, which was complemented by the Tukey multiple comparison test with a 5 per cent significance level. The means of the antero-posterior linear distances for the oropharynx were similar. For the oropharynx, the values found for the CBCT lateral reconstructions were similar to the other two methods, though a statistically significant difference was observed between the axial cut and the lateral cephalograms.

Pearson correlation coefficient ( $P < 0.001$ ) was used to assess the correlation between linear measurement and the



**Figure 1** Airway measurements on the sagittal and axial plane: lines that intersect the anterior and posterior pharyngeal walls on cone-beam computed tomography.

**Table 1** Upper airway measurements analysed in the study. CBCT: cone-beam computed tomography.

Distance	Airway			
	Nasopharynx		Oropharynx	
	Mean (mm)	Standard deviation	Mean (mm)	Standard deviation
Axial slice (CBCT)	16.14 <sup>B</sup>	±2.81	9.81 <sup>B</sup>	±3.01
Lateral reconstruction (CBCT)	16.61 <sup>B</sup>	±3.03	10.53 <sup>BA</sup>	±3.32
Lateral cephalogram	15.97 <sup>B</sup>	±3.27	10.75 <sup>A</sup>	±2.68

Means with different letters were significant when tested by analysis of variance randomized block design (complemented by Tukey multiple comparison test at the 5 per cent significance level).

**Table 2** Upper airway area measurements: correlation of the distances found with cone-beam computed tomography (CBCT) axial slice, CBCT lateral reconstruction, and lateral radiography.

	Airway	
	Nasopharynx	Oropharynx
	Superior axial area	Inferior axial area
Axial slice (CBCT)	0.89***	0.76***
Lateral reconstruction (CBCT)	0.85***	0.80***
Lateral radiograph	0.81***	0.52***

Asterisks indicate positive correlation as tested under Pearson correlation coefficient ( $P < 0.001$ ).

corresponding area within the different images. Naso- and oropharynx linear measurements in both axial slices, CBCT lateral reconstructions, and lateral cephalograms revealed a positive correlation with area measurements observed on the axial slices (Table 2).

## Discussion

The main objective of this research was to compare airway space on different orientation planes and the performance of conventional radiographs (a classic imaging method chosen by orthodontists for cephalometric analysis) with CBCT volumetric data, which provide a three-dimensional visualization.

Several studies have proposed an array of measuring methods concerning airway assessment in different groups of patients (Filho *et al.*, 2001; Baik *et al.*, 2002; Lagravere and Major, 2005; Moshiri *et al.*, 2007; Ogawa *et al.*, 2007). However, landmark identification and measurement execution is still affected by considerable subjectivity. In this study, the reference points used to trace linear

measurements were the palatal plane extension to the nasopharynx and the lower border of the mandibular intersection with the posterior border of the tongue extending to the oropharynx, both with the palatal plane parallel to the floor. These measurements were chosen so that standardization of easily identifiable points on planes could be achieved, allowing reproducibility of measurements.

The initial purpose of the study was to determine linear measurements of the airway in an antero-posterior view to the naso- and oropharynx, according to the type of examination performed. CBCT axial images allow obtainment of these measurements without the interference of neighbouring soft tissues. On the other hand, with sagittal plane images, both CBCT reconstructions and lateral cephalograms, interference might result due to superimposition of the structures, particularly on the nasopharynx, where hypertrophic tissues are commonly observed.

The results showed that the values for the nasopharynx on the axial plane, in the profile CBCT reconstruction and in the lateral cephalograms, were statistically similar. An increase of the oropharynx was observed, though without a statistically significant difference, when the axial cut was compared with the CBCT lateral reconstruction, and also with the radiograph. However, when the linear measurements of the axial slices were compared with the lateral cephalograms, a statistically significant increase was noted.

Moshiri *et al.* (2007) assessed the accuracy of a number of cephalometric measurements using dry human skulls, comparing different CBCT reconstructions with lateral cephalograms. Their conclusions suggest that measurements of two-dimensional reconstructions are nearly the actual values. For radiographs, though, those that diverged had a magnification range of 4.6–9.1 per cent. Kumar *et al.* (2008) compared cephalometric angles and linear measurements of conventional and magnified CBCT images with radiographic images and concluded that linear measurements were not significantly different.

In the present study, a higher statistically significant mean was observed in the oropharynx when compared with the axial slices. This finding may be explained by the fact that the assessment comprised soft tissue points formed by the projection of shaded areas, which may have hampered assessment with conventional radiographs. Studies that employed hard tissues points and dry skulls on the other hand were not affected by this limitation (Moshiri *et al.*, 2007).

As regards the evaluation of the antero-posterior linear measurement and its respective area, it was possible to establish a positive correlation for all radiographic types of examination of both the naso- and oropharynx. This revealed that increases or decreases in linear measurements indicate an airway alteration at the corresponding area. Filho *et al.* (2001), in a study of two auxiliary diagnostic methods of nasopharynx airway obstruction, endoscopy

and radiography, found a high sensitivity and a low specificity of the radiographic diagnosis when compared with endoscopic diagnosis.

Ogawa *et al.* (2007) used CBCT volumetric images in order to evaluate patients diagnosed with obstructive apnoea, compared with control subjects. Airway measurements on axial slices showed a significantly decreased airway volume, area, and distances in subjects with apnoea. The conclusions reached by those authors indicate the importance of CBCT in the diagnosis of this condition.

Since clinicians generally consider lateral radiographs as a reliable instrument for cephalometric analysis and upper airway evaluation, this study was designed to estimate the possibility that airway constrictions occasionally represented on sagittal images of laterally positioned hypertrophic tissues are not correlated in axial visualizations. Nevertheless, in spite of the difference found between the radiographs and the corresponding axial cut in the oropharynx, the results demonstrate a correlation between linear and area measurements, independent of the type of method used. This reliability of cephalometric analysis in terms of upper airway evaluation, both with radiographic and CBCT images, may serve as a guide during the different stages of orthodontic treatment, and when appropriate may promote patient referral to the appropriate medical specialist.

## Conclusion

The results indicate that airway linear measurements are reliable, with both lateral cephalograms and CBCT reconstruction, as there is a positive correlation with the respective area measurements on axial slices.

## References

- Araki K *et al.* 2004 Characteristics of a newly developed dentomaxillofacial X-ray cone beam CT scanner (CB MercuRay): system configuration and physical properties. *Dentomaxillofacial Radiology* 33: 51–59
- Baik U B, Suzuki M, Ikeda K, Sugawara J, Mitani H 2002 Relationship between cephalometric characteristics and obstructive sites in obstructive sleep apnea syndrome. *Angle Orthodontist* 72: 124–134
- Bittencourt M 2002 Dimensão do espaço nasofaríngeo em indivíduos portadores de maloclusão de Classe II. *Ortodontia* 16–30
- Farman A G, Scarfe W C 2006 Development of imaging selection criteria and procedures should precede cephalometric assessment with cone-beam computed tomography. *American Journal of Orthodontics and Dentofacial Orthopedics* 130: 257–265
- Filho D I, Raveli D B, Raveli R B, De Castro Monteiro Loffredo L, Gandin L G Jr 2001 A comparison of nasopharyngeal endoscopy and lateral cephalometric radiography in the diagnosis of nasopharyngeal airway obstruction. *American Journal of Orthodontics and Dentofacial Orthopedics* 120: 348–352
- Fujiki P, Rossato C 1999 Influência da hipertrofia adenoideana no crescimento e desenvolvimento craniofacial. *Ortodontia* 32: 70–79
- Holberg C, Steinhäuser S, Geis P, Rudzki-Janson I 2005 Cone-beam computed tomography in orthodontics: benefits and limitations. *Journal of Orofacial Orthopedics* 66: 434–444
- Kumar V, Ludlow J, Soares Cividanes L H, Mol A 2008 *In vivo* comparison of conventional and cone beam CT synthesized cephalograms. *Angle Orthodontist* 78: 873–879
- Lagrave M O, Major P W 2005 Proposed reference point for 3-dimensional cephalometric analysis with cone-beam computerized tomography. *American Journal of Orthodontics and Dentofacial Orthopedics* 128: 657–660
- McNamara J A 1981 Influence of respiratory pattern on craniofacial growth. *Angle Orthodontist* 51: 269–300
- Moshiri M, Scarfe W C, Hilgers M L, Scheetz J P, Silveira A M, Farman A G 2007 Accuracy of linear measurements from imaging plate and lateral cephalometric images derived from cone-beam computed tomography. *American Journal of Orthodontics and Dentofacial Orthopedics* 132: 550–560
- Mozzo P, Procacci C, Tacconi A, Martini P T, Andreis I A 1998 A new volumetric CT machine for dental imaging based on the cone-beam technique: preliminary results. *European Radiology* 8: 1558–1564
- Nuernberg C H G, Vilella O V 2006 Avaliação Cefalométrica da Orofaringe. *Revista Odonto Ciência—Faculdade Odontologia/PUCRS* 21: 370–375
- Ogawa T, Enciso R, Shintaku W H, Clark G T 2007 Evaluation of cross-section airway configuration of obstructive sleep apnea. *Oral Surgery, Oral Medicine, Oral Pathology, Oral Radiology, and Endodontology* 103: 102–108
- Scarfe W C, Farman A G, Sukovic P 2006 Clinical applications of cone-beam computed tomography in dental practice. *Journal of the Canadian Dental Association* 72: 75–80
- Solow B, Siersbæk-Nielsen S, Greve E 1984 Airway adequacy, head posture, and craniofacial morphology. *American Journal of Orthodontics* 86: 214–223
- Subtelny J D, Baker H K 1956 The significance of adenoid tissue in velopharyngeal function. *Plastic and Reconstructive Surgery* 17: 235–250
- Watson R M, Warren D W, Fischer N D 1968 Nasal resistance, skeletal classification, and mouth breathing in orthodontic patients. *American Journal of Orthodontics* 54: 367–379